

Hall technique for the management of carious primary molar teeth among African children - a review

Obehi. O Osadolor

Department of Child Dental Health, University of Nigeria Teaching Hospital, Ituku- ozalla, Enugu State, Nigeria

Abstract

Background: Hall technique involves cementing preformed metal crowns or stainless steel crowns on the tooth with the use of luting glass ionomer cements, without the use of local anaesthesia, caries removal and tooth preparation of any kind. It can be an intervention to stop the progression of active untreated carious lesion in primary molar teeth among African children. This article reviews the available studies on Hall technique used for the management of carious primary molar teeth among African children.

Method: An electronic literature search in Web of science, Scopus, PubMed, Google Scholar, African journals online, ResearchGate and Google was conducted in June, 2023 using the Population-Concept-Context framework. Search terms and keywords were combined by Boolean operators. Three independent investigators (research assistants) screened titles, abstracts and full text of publications. The inclusion criteria were original research articles, case report, case series related to Hall technique for the management of carious primary molar teeth studies conducted in African continent, published in English language and in electronic databases.

Results: Four articles were included as they were assessed to meet the aim of the review. The study design of the articles was three randomised controlled clinical trial and one case report. One study was identified each from Egypt, Morocco, Nigeria and Sudan respectively. All the identified studies in African continent were hospital based.

Conclusion: Hall technique can be an intervention for management of carious primary molar teeth in resource poor locality in Africa and globally. Studies on Hall technique for the management of carious primary molar teeth identified in Africa were few and restricted to few countries.

IMC J Med Sci. 2024; 18(1):003. DOI: <https://doi.org/10.55010/imcjms.18.003>

Introduction

There are many techniques for managing carious primary teeth among children. Hall technique is one of the non-invasive methods of managing carious primary molars [1]. The technique involves the removal of food debris by use of hand instruments, without any use of local anaesthesia, caries removal and tooth preparation of any kind, and cementing preformed metal crowns or stainless steel crowns on the tooth with the use of luting glass ionomer cements [2]. In Hall technique for managing carious primary molar teeth, dental caries in tooth/teeth is

sealed under preformed metal crowns [1]. Hall technique is not suitable for every child and every carious primary molar tooth. There are selection criteria that should be assessed before considering or recommending the technique to a child, parent or caregiver. Orthodontic elastic separators are placed between the tight contact point of the primary molar using two pieces of dental floss or an elastic separator placing pliers [3]. The elastic separators are left in place for about five to seven days. The use of Hall technique for managing carious primary molar teeth in resource poor settings requires minimal

*Correspondence: Obehi. O Osadolor, University of Nigeria Teaching Hospital, Ituku- ozalla, Enugu State, Nigeria.
E-mail: osadolorobehi@yahoo.com

training, simple armamentarium and minimal support. The aim of this article is to review the available studies on Hall technique for the management of carious primary molar teeth among African children. The success rate, minor and major failures rate of preformed metal crowns placed using Hall technique is also reviewed among the identified studies in Africa continent.

Materials and methods

The review focused on published primary articles on Hall technique for the management of carious primary molar teeth in children and conducted in African region.

Literature search method: An electronic literature search in Web of science, Scopus, PubMed, Google Scholar, African journals online, ResearchGate and Google was conducted in June, 2023 using the Population-Concept-Context framework [4]. Framework included: (a) population: children, pre-school children, (b) concept: Hall technique for the management of carious primary molar teeth, and (c) context: studies carried out in Africa continent, published in English language and in electronic databases.

The keywords used were Hall technique, carious teeth, deciduous molars, primary teeth, primary molars, Africa countries, sub-Saharan Africa, deciduous teeth, African region, Africa continent, African population, African people, sub-Saharan countries, African children, Oral health practitioner, African Dentist and Africa. Search terms and keywords were combined by Boolean operators. Three independent investigators (research assistants) screened titles and abstracts of publications on Hall technique for the management of carious primary molar teeth studies, and potential references to identify which studies met the inclusion criteria of this review. Information was extracted from the full texts of articles regarding the location of the research and the main content. The inclusion criteria were original research articles, case report, case series related to Hall technique for the management of carious primary molar teeth conducted in African region, published in English language and in electronic databases. Review articles, systematic reviews, viewpoints, books, letters, editorials, book chapters, perspectives, and news related to Hall

technique for the management of carious primary molar teeth were excluded. Study data of the included articles were extracted and collated in a table, including study details, author(s), year of publication, study population, study location or country, study objectives and design. Sample size, success rate, minor and major failure rate and period of assessment were also extracted from identified studies and collated in a table. All identified studies in Africa were included and if relevant data were missing, the authors of the articles were contacted for additional information via e-mail. No specified time frame was used during the search, any additional studies in African region identified from the reference lists of published papers were retrieved from the web using Google scholar and Google search engines.

Results

Seventy six articles were identified; fifty duplicates were removed during screening. Abstracts and full texts were screened using inclusion criteria by three independent research assistants. Twenty two articles were excluded because they did not meet the inclusion criteria. Four articles were finally included as they were assessed to meet the aim of the review. Four articles included were three randomised controlled clinical trial and one case report (Figure-1). One study was conducted in

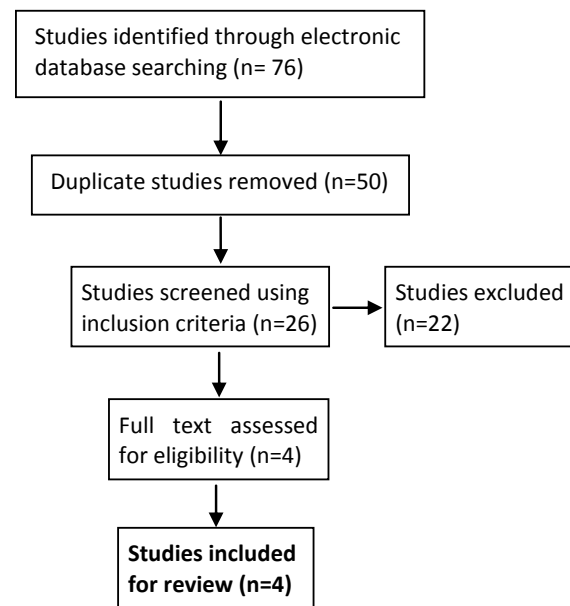


Figure-1: Flow chart showing inclusion and exclusion of studies

Egypt, Morocco, Nigeria, and Sudan respectively among the articles eligible for review. Summary of identified studies conducted in African countries for management of carious primary molar teeth using Hall technique is shown in Table-1.

All the identified studies included in this review used defined criteria for success and failure of Hall technique for the management of carious primary molar teeth among African children. Table-2 summarized the criteria used to assess the success

Table-1: Summary of identified studies on Hall technique for management of carious primary molar teeth conducted in African countries

Author/Year of publication	Study population and study design	Study objective	Country of study
Hariri et al [5], 2016	4 years old child Case report	To describes the treatment strategy for early childhood caries in mandibular first primary molars, in a young patient who was 4 years old, using the Hall technique	Morocco
Elamin et al [6], 2019	5 to 8 years old children Randomised clinical trial	To compare the clinical performance, success rate and cost-effectiveness of preformed metal crowns placed by either the conventional techniques or Hall technique.	Sudan
Sharaf et al [7], 2021	4 to 8 years old children Randomised controlled trial	To compare the clinical and radiographic success of the stainless steel crowns placed by the Hall technique to the conventional method in restoring carious primary molars.	Egypt
Ayedun et al [3], 2021	3 to 8 years old children Randomised controlled clinical trial	To assess and compare the primary and secondary treatment outcomes of stainless steel crown restorations using the conventional method and the Hall technique in primary molars.	Nigeria

Table-2: Criteria for success, major and minor failures of preformed metal crowns placed using Hall technique for the management of carious primary molar teeth in the identified studies

Success criteria	Major failure criteria	Minor failure criteria
Restoration is satisfactory, no intervention required, no clinical signs or symptoms of pulp pathology, crown is not showing any signs of major or minor failures. Radiographically no evidence of periapical radiolucency, internal or external root resorption and widening of periodontal ligament space.	Presence of irreversible pulpitis or dental fistula/abscess, requiring pulpectomy or extraction, loss of restoration/crown and tooth not capable of being re-restored. Radiographically evidence of periapical radiolucency, internal or external root resorption and widening of periodontal ligament space.	Secondary caries or new lesions detected clinically, presence of preformed metal crown perforation without pain, restoration fracture or wear and intervention required. Loss of restoration/crown and tooth can be re-restored, or able to be retreated. Reversible pulpitis - could be treated without the need for extraction or pulpotomy.

Table-3: Summary of success and failure rates of preformed metal crowns placed using Hall technique for management of carious primary molar teeth among African children in the identified studies

Author/Year of publication/ Country	Sample size	Success rate/ Period of assessment	Major failure rate/ Period of assessment	Minor failure rate/ Period of assessment
Elamin et al [6], 2019, Sudan	86 children with 109 preformed metal crowns on selected teeth	93.6% at 24 months follow-up	6.4% at 24 months follow-up	2.7% at 24 months follow-up
Sharaf et al [7], 2021, Egypt	52 children with 52 preformed metal crowns on selected teeth	100 % at 1 week and 1 months follow up, 94.2% at 6 and at 12 months follow up	1.9% at 6 and 12 months follow up	3.9% at 6 months and at 12 months follow up
Ayedun et al [3], 2021, Nigeria	25 children with 25 preformed metal crowns on selected teeth	100% at 12 months review	0% at 12 months review	0 % at 12 months review

and failures of the Hall technique in the identified studies.

In Sudan, the survival rate was 94.5% at 12 months and 93.6% at 24 months follow up. Overall failure rate was 9.2 % and success rate was 90.8% at 24 months follow up, while the dropout rate was 3.7%, 4.6%, 12.8% and 22.9% at 6, 12, 18 and 24 months follow-ups respectively. In Egypt, the success rate was 94.2% and failure rate was 5.8% at 6 and 12 months follow up respectively, while in Nigeria, the failure rate was 0% and success rate was 100% at 12 months follow-up (Table-3).

Discussion

The level of untreated dental caries in primary teeth among African children is high [8]. Hall technique with preformed metal crowns can be an intervention for preventing the progression of active carious lesion in primary molar teeth. The selected teeth for this technique are single surface or multi-surface enamel or dentine caries that are symptomless, non-mobile, cavitated or non-cavitated carious lesion, with no clinical or radiographic signs of pulpal pathology [3,5-7]. The use of the technique might not be common in low income countries or resource limited environment

in Africa and globally, because of non-availability of preformed metal crowns or stainless steel crowns, level of training, need for training and need for patient co-operation [6]. This review identified studies on Hall technique for carious primary molar teeth from four countries [3,5-7] in African region. All of them were hospital based studies though this technique can be carried out in community based setting with simple armamentarium. The success rate, minor and major failures rate of preformed metal crowns placed using Hall technique was also reviewed among the identified studies in African continent. In Egypt, the success rate was 94.2%, failure rate was 5.8% at 6 and 12 months follow up respectively [7]. In Nigeria, the success rate was 100% and 0% failure rate at 12 months follow up [3]. In Sudan, the criteria for assessment used were minor failures when there was dislodgement or perforation of the preformed metal crown without pain while major failures were associated with pain and needed pulp therapy or extraction. Success was considered when there was absence of minor and major failures [6]. The success rate was 90.8% and failure rate was 9.2% in Sudan at 24 months review [6]. The calculated mean cost per unit was cheaper in Hall technique than the conventional stainless steel crown technique. Preformed metal crowns

placed by Hall technique were more cost-effective than the conventional stainless steel crown technique [6]. The mean procedure time in Hall technique was also shorter than the conventional stainless steel crown technique [3,6-7]. Hall technique had been shown to be more advantageous in term of time and cost [3,6], but some dentists from general dental practice did not routinely use preformed metal crown for managing carious primary molars because of lack of training, perceived lack of cost-effectiveness in general practice, and need for patient cooperation [6]. Four studies analysed in this review might not reflect the diverse ethnic population and situation in Africa. Some parents and children in Africa might have concerns on the aesthetic appearance of the preformed metal crowns. More studies on use of Hall technique from various countries and ethnic groups in Africa are required to fill the existing knowledge gaps of the dental caregivers.

Conclusion

The armamentarium for Hall technique is simple and it could be used in underserved and un-served African children population with active carious lesions in primary molar teeth. The studies identified in Africa continent were few. More studies from other African countries are needed to add to the existing knowledge and literature.

Financial support and sponsorship

None.

Conflicts of interest

No competing interest/conflict of interest.

Acknowledgements

Author wishes to thank all the colleagues who helped in searching and screening of articles.

References

1. Altoukhi DH, El-Housseiny AA. Hall technique for carious primary molars: a review of the literature. *Dent J (Basel)*. 2020 17; **8**(1): 11. doi: 10.3390/dj8010011.
2. Innes NP, Evans DJ, Bonifacio CC, Geneser M, Hesse D, Heimer M, et al. The Hall Technique 10 years on: questions and answers. *Br Dent J*. 2017; **222**(6): 478-483. doi: 10.1038/sj.bdj.2017.273.
3. Ayedun OS, Oredugba FA, Sote EO. Comparison of the treatment outcomes of the conventional stainless steel crown restorations and the Hall technique in the treatment of carious primary molars. *Niger J Clin Pract*. 2021; **24**: 584-594. doi: 10.4103/njcp.njcp_460_20.
4. Glonti K, Cauchi D, Cobo E, Boutron I, Moher D, Hren D. A scoping review protocol on the roles and tasks of peer reviewers in the manuscript review process in biomedical journals. *BMJ Open*. 2017; **7**: e017468. doi:10.1136/bmjopen-2017-017468.
5. Hariri M, Ramdi H, El Alloussi M, Chhoul H. The Hall technique: a non-conventional method for managing carious primary molars. *Dentistry*. 2016; **6**(7): 385. doi: 10.4172/2161-1122.1000385.
6. Elamin F, Abdelazeem N, Salah I, Mirghani Y, Wong F. A randomized clinical trial comparing Hall vs. conventional technique in placing preformed metal crowns from Sudan. *PLoS One*. 2019; **14**(6): e0217740. doi: 10.1371/journal.pone.0217740.
7. Sharaf DA, Dowidar K, Habashy LM, Hamed H. Hall technique versus the conventional stainless steel crowns restoring carious primary molar teeth: a randomized controlled clinical trial. *Alex Dent J*. 2021; **46**(3): 174-180. doi: 10.21608/adjalexu.2021.47605.1117.
8. Osadolor OO. Dental caries and access to oral health services among children and adolescents. *Janaki Med Coll J Med Sci*. 2022; **10** (3): 64-70.

Cite this article as:

Osadolor OO. Hall technique for the management of carious primary molar teeth among African children - a review. *IMC J Med Sci*. 2024; 18(1):003.
DOI: <https://doi.org/10.55010/imcims.18.003>